

Background and aim

Pancreatic neuroendocrine tumors (NETs) are rare neoplasms whose prognosis and management depend on TNM staging, Ki-67 proliferative index and the presence of symptoms secondary to hormone production. The European Neuroendocrine Tumor Society (ENETS) proposes a follow-up approach rather than an immediate resection for small, non-functioning, asymptomatic lesions, given their low risk of malignant evolution. This wait and see strategy, based on high-resolution imaging techniques, allows an early recognition and resection in case of malignant progression. This case report describes the clinical role of EUS in the diagnosis and the follow-up in this setting.

Material and methods

Among the available high quality imaging modalities, EUS with tissue acquisition, sonoelastography and contrast-enhanced imaging is particularly accurate for the detection, the histological confirmation, the Ki-67 quantification and the follow-up of very small pancreatic NETs.

Results

Several years ago an asymptomatic women had an EUS diagnosis of a 13 mm hypoechoic lesion in the pancreatic body; biochemistry revealed normal blood levels of CA 19-9, CEA, Chromogranin A. Although FNA was negative, in presence of a provisional diagnosis of a NET, the patient was followed-up. Due to her suspected allergy to contrast agents, the patient refused to undergo TC scan or MRI. In the following four years the lesion appeared unmodified at EUS, a second FNA was still negative, and either contrast-enhanced EUS or sonoelastography showed a benign pattern (Figure 1); the patient was still asymptomatic. One year later the lesion enlarged up to 20 mm, with a worsening of contrast-enhanced imaging and sonoelastography (Figure 2); FNB found a well-differentiated G1 NET. Given this evolution and the upstream dilation of the Wirsung duct, we suggested a surgical treatment. After distal pancreatectomy the final diagnosis was a G2 NET.

Conclusions

This is a case of a small pancreatic focal lesion with a long-lasting EUS benign pattern and negative cytology, that almost 7 years after the initial diagnosis changed its EUS and histological features showing to be a G2 NET. This lesion was probably a NET since the beginning, but its high grade of differentiation and the use of smear cytology caused a false negativity of the first two FNAs. Nevertheless, a long-term follow up with the new high quality EUS devices available allowed for a correct diagnosis of NET once the tumor changed its biological behavior.

Figure 1

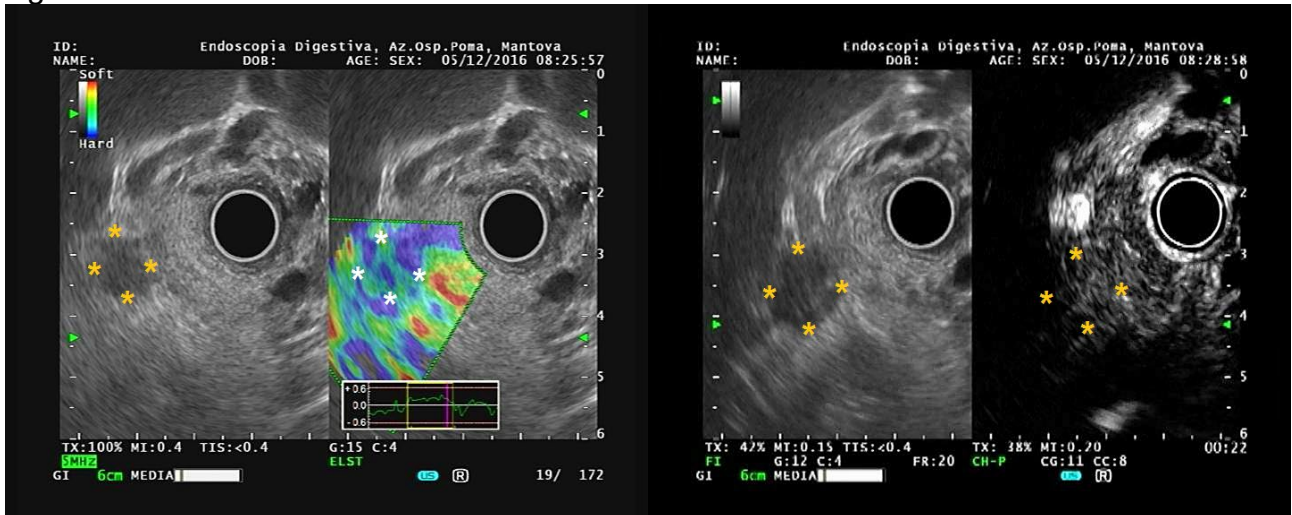


Figure 2

